

Identification of Hemotropic *Mycoplasmas* in an Eastern Box Turtle (*Terrapene carolina carolina*) and a Yellow-Bellied Slider (*Trachemys scripta scripta*) from North Carolina

Jo Jarred,¹ Gregory Lewbart,^{1,2} Kelsey Stover,¹ Brittany Thomas,¹ Ricardo Maggi,¹ and Edward B. Breitschwerdt¹ ¹Department of Clinical Sciences and the Comparative Medicine Institute, North Carolina State University College of Veterinary Medicine, Raleigh, North Carolina 27607, USA; ²Corresponding author: (email: greg_lewbart@ncsu.edu)

ABSTRACT: *Mycoplasma* spp. are known from several chelonian and other reptilian species. We determined if turtles obtained by the Turtle Rescue Team at North Carolina State University are carriers of hemotropic *Mycoplasma* or *Bartonella* spp. Spleen samples were collected at necropsy during May through July, 2014 from 53 turtles of seven species. All turtles were dead or were euthanized upon arrival due to severe traumatic injuries, or they died shortly after beginning treatment. We used PCR amplification for both bacterial genera; *Bartonella* spp. DNA was not amplified. Based upon sequencing of the 16S rRNA subunit, one eastern box turtle (*Terrapene carolina carolina*) and one yellow-bellied slider (*Trachemys scripta scripta*) were infected with *Mycoplasma* spp. that have genetic similarities to strains that infect other animals.

Key words: Chelonian, hemoplasma, hemotropic mycoplasma, PCR, wildlife.

Identification of vector-borne diseases in reptiles has largely been unexplored. Our project was inspired by the documentation of *Bartonella* spp. in sea turtles in North Carolina (Valentine et al. 2007), because subsequent investigations of reptiles, including terrestrial turtles, as a possible reservoir host remained lacking. Various *Bartonella* spp. have been identified in North Carolina cetaceans (Harms et al. 2008; Maggi et al. 2008) and river otters (Chinnadurai et al., 2010). Also, known and novel *Mycoplasma* spp. have been documented in reptiles, the majority of which are associated with clinical signs involving the respiratory tract (Brown et al. 2001; Feldman et al. 2006; Ossiboff et al. 2015). Hemotropic mycoplasmas (hemoplasmas) are small, epicellular, cell wall-deficient bacteria encountered in the blood of a variety of animal species that can contribute to pathogenic outcomes such as anemia, ill-thrift,

and infertility (Messick 2004). Although it has been determined that hemoplasmas share phenotypic and genetic similarities with other *Mycoplasma* spp., variability in the genomes of these bacteria continue to complicate exact classification at the species level (Guimaraes et al. 2014). Different hemoplasma species are zoonotic and cause the same effects on red blood cells in human patients as they do in other mammals (Sykes et al. 2010; Steer et al. 2011). Clinical signs and pathogenic properties (if any) associated with hemoplasmas in reptiles are unknown.

The North Carolina State University College of Veterinary Medicine Turtle Rescue Team (TRT) is a student-run organization of volunteers who rehabilitate wild reptiles (Lewbart et al. 2005). Between May and July 2014, samples of 53 spleens were collected from turtles admitted to the TRT that either died or were euthanized, mostly due to trauma (mainly vehicular). The 53 specimens included 23 eastern box turtles (*Terrapene carolina carolina*), 14 yellow-bellied sliders (*Trachemys scripta scripta*), six river cooters (*Pseudemys concinna*), five eastern painted turtles (*Chrysemys picta*), three common snapping turtles (*Chelydra serpentina*), one common mud turtle (*Kinosternon subrubrum*), and one common musk turtle (*Sternotherus odoratus*). Turtles originated from central North Carolina. After death, specimens were stored at 4 C for up to 2 d until tissue harvest. We performed necropsies with the guidance of a sea turtle necropsy manual (Work 2000) using appropriate modifications made for each species. If DNA extraction could not be performed immediately, spleen specimens (up to 5 g, depending on the size of

turtle) were harvested and stored frozen at 0 C in 5 mL screw-cap centrifuge tubes.

Spleen specimens were thawed or cut directly after necropsy into small pieces using a scalpel blade. Pathogen DNA extraction was performed with a standardized kit (DNeasy Blood & Tissue Kit; Qiagen, Valencia, California, USA), following the manufacturer's instructions for DNA extraction from tissues. Pathogen DNA concentrations and absorbance ratios at 260 nm and 280 nm were determined using the Nanodrop® ND-1000 (Thermo, Wilmington, Delaware, USA). To assess the concentration and purity of the DNA samples collected. Repeated DNA extractions were performed in eight cases to ensure that yields were >15 ng/μL.

We used pathogen DNA amplification, through PCR, to detect the presence of *Bartonella* spp. and hemotropic *Mycoplasma* spp. DNA in each sample. We amplified hemotropic *Mycoplasma* by targeting a conserved region of the 16SrRNA using oligonucleotides HemMycop16S-322s: 5' GCC CAT ATT CCT ACG GGA AGC AGC AGT 3' and HemMyco16S-938as: 5' CTC CAC CAC TTG TTC AGG TCC CCG TC 3' as previously described (Maggi et al. 2013). Detection of *Bartonella* DNA was performed by targeting the 16S–23S intergenic spacer region (ITS) using oligonucleotides 325s (5' CCTCAGAT GATGATCCCAAGCCTTTTGGCG 3') and 1000as (5' CTGAGCTACGGCCCCCTAAAT CAGG 3') as forward and reverse primers, respectively (Valentine et al. 2007). Amplification for each genus was performed in a 25 μL final volume reaction. The 25 μL reaction mix contained 12.5 μL of MyTaq™ Red Mix (Bioline, Taunton, Massachusetts, USA), 0.2 μL of 50 μM of each forward and reverse primer (IDT® DNA Technologies, Coralville, Iowa, USA), 7.3 μL of molecular grade water, and 5 μL (75–150 ng total) of template DNA. We prepared positive controls using either 5 μL *Mycoplasma hematoparvum* 16SrRNA or *Bartonella henselae* ITS plasmid vectors (pGEM-T Easy Vector Systems, Promega, Madison, Wisconsin, USA) at a final concentration of five copies per microliter, for both *Mycoplasma* and *Bartonella* detection. Ampli-

fications were performed in an Eppendorf Mastercycler EPgradient S® (Eppendorf, Hauppauge, New York, USA).

We used 2% agarose gel electrophoresis to analyze PCR products, with detection using ethidium bromide under ultraviolet light. *Bartonella* spp. DNA was not amplified from any turtle spleen. Two turtle spleens contained *Mycoplasma* spp. DNA. Amplicon products were sequenced by Genewiz (RTP, North Carolina, USA) to establish species strain identification using chromatogram and alignment analysis (ContigExpress® and AlignX software, Vector NTI® v10, Invitrogen, Carlsbad, California, USA). After sequencing, phylogenetic and taxonomic comparisons were made using GenBank. The DNA sequence from the eastern box turtle number 24 (GenBank accession number MG649987) was most similar to the following *Mycoplasma* sequences: 87% (490/564 base pairs [bp]) similar to Mycoplasmataceae bacterium T2110, (GenBank: DQ318957.1), an unclassified mycoplasma found in Atlantic Cod (*Gadus morhua*); 87% (484/557 bp) similar to Candidatus *Mycoplasma haemohominis*, found in humans; and 92% (483/564 bp) similar to Candidatus *Mycoplasma haemominutum*, found in cats (Fig. 1). The DNA sequence from yellow-bellied slider number 47 (GenBank accession number MG519832) was most similar to the following *Mycoplasma* sequences: 92% (514/557 bp) similar to *Mycoplasma insons*, previously found in green iguanas; 92% (514/557 bp) similar to *Mycoplasma cavipharyngis*, found in guinea pigs (*Cavia porcellus*); 92% (512/557 bp) similar to *Mycoplasma fastidiosum*, found in equines (Fig. 2).

Hemotropic *Mycoplasma* spp. have not previously been amplified from a reptile. The potential clinical impact that hemotropic *Mycoplasma* spp. have on reptiles is unknown because their pathogenicity in reptile species remains undetermined. Many turtles enter a rehabilitation facility already in compromised health, and stresses associated with trauma and rehabilitation can exacerbate what would otherwise be nonclinical or minor health issues. If hemotropic *Mycoplasma* spp. are

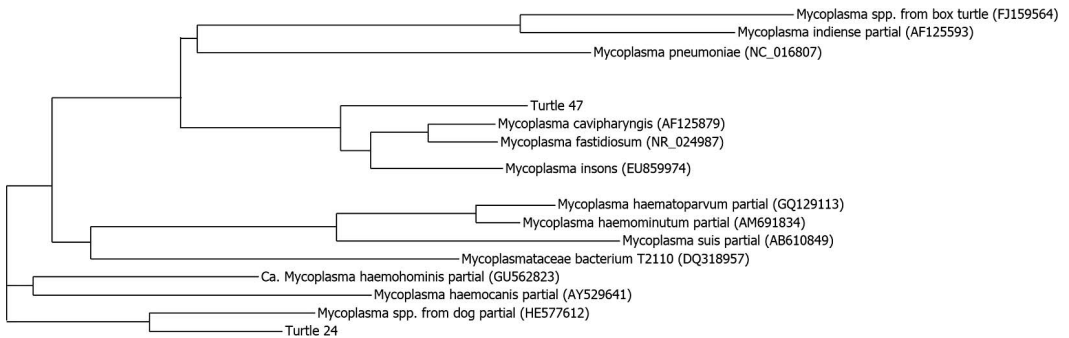


FIGURE 1. Sequencing results highlighting the similarities between the *Mycoplasma* spp. identified in turtle number 24 (eastern box turtle, *Terrapene carolina carolina*) and turtle number 47 (yellow-bellied slider, *Trachemys scripta scripta*) to each other as well as to species of *Mycoplasma* found in canines and felines.

normally nonpathogenic in chelonian species, hemoplasmosis could have a negative impact on an animal's recovery and chance for ultimate release for those animals in rehabilitation facilities where concurrent diseases can exacerbate nonpathogenic conditions.

We do not know if the *Mycoplasma* spp. in chelonians are contagious to humans or to other animal species. Hemotropic *Mycoplasma* spp. amplified from reservoir hosts, including bats (Mascarelli et al. 2014), deer (Maggi et al. 2013), raccoon (*Procyon lotor*; Frerichs and Holbrook 1971), rodents (Elko and Cantrell 1968), and other animals (Messick 2004), might serve as sources for human infections. Zoonotic diseases such as *Salmonella* spp. and Eastern Equine Encephalitis virus have occurred following contact with nonclinical reptiles (White 2011; Middleton 2014). We used splenic extracts in our analyses and presumed that the *Mycoplasma* spp. was present in erythrocytes and not in splenic stroma.

Although we did not amplify DNA from a *Bartonella* spp. from terrestrial turtles in this study, a negative PCR result does not rule out a potential *Bartonella* spp. infection. In non-reservoir hosts, *Bartonella* spp. are most often found in very low concentrations in blood and splenic tissues, which could result in false negative PCR amplification. The role, if any, which reptiles play in transmission of *Mycoplasma* is unknown, and further investigation into hemotropic *Mycoplasma* and other blood pathogens is necessary. Our study provided additional information supporting the presence in reptiles of hemotropic *Mycoplasmas*, which were genetically very similar to pathogenic strains found in humans and other mammals. Until further investigation has evaluated the pathogenicity and spread of hemotropic *Mycoplasma* in reptiles, isolation of turtles with compromised health status, maintaining cleanliness and sterility of surgical and medical rehabilitation supplies or use of separate supplies for infected turtles, and having personal protective equipment for

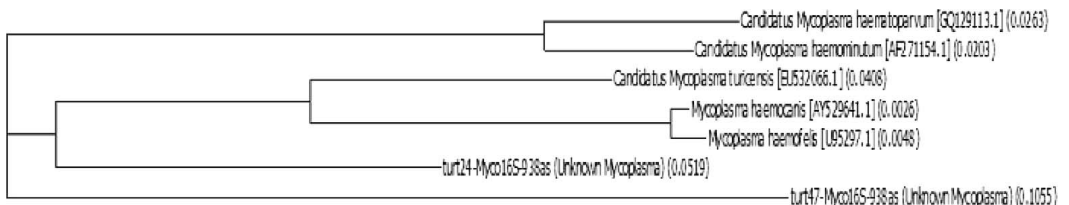


FIGURE 2. The relationship between the novel *Mycoplasma* species in turtle number 24 (eastern box turtle, *Terrapene carolina carolina*) and turtle number 47 (yellow-bellied slider, *Trachemys scripta scripta*) to each other and to known *Mycoplasma* spp. using the 550 base pair region of 16S ribosomal RNA gene.

individuals handling potentially infected turtles might be indicated.

We thank the Robert J. Koller Aquatic Animal Medicine Research Endowment for financial support and the Turtle Rescue Team students who assisted in the procurement of specimens and samples.

LITERATURE CITED

- Brown MB, Brown DR, Klein PA, McLaughlin GS, Schumacher IM, Jacobson ER, Adams HP, Tully JG. 2001. *Mycoplasma agassizii* sp. nov., isolated from the upper respiratory tract of the desert tortoise (*Gopherus agassizii*) and the gopher tortoise (*Gopherus polyphemus*). *Int J Syst Evol Microbiol* 51: 413–418.
- Chinnadurai SK, Birkenheuer AJ, Blanton HL, Maggi RG, Belfiore N, Marr HS, Breitschwerdt EB, Stoskopf MK. 2010. Prevalence of selected vector-borne organisms and identification of *Bartonella* species DNA in North American river otters (*Lontra canadensis*). *J Wildl Dis* 46:947–950.
- Elko EE, Cantrell W. 1968. Phagocytosis and anemia in rats infected with *Haemobartonella muris*. *J Infect Dis* 118:324–332.
- Feldman SH, Wimsatt J, Marchang RE, Johnson AJ, Brown W, Mitchell JC, Sleeman JM. 2006. A novel *Mycoplasma* detected in association with upper respiratory disease syndrome in free-ranging eastern box turtles (*Terrapene carolina carolina*) in Virginia. *J Wildl Dis* 42: 279–289.
- Frerichs WM, Holbrook AA. 1971. *Haemobartonella procyoni* sp. n. in the raccoon, *Procyon lotor*. *J Parasitol* 57:1309–1310.
- Guimaraes AS, Santos AP, do Nascimento NC, Timenetsky J, Messick JB. 2014. Comparative genomics and phylogenomics of hemotropic mycoplasmas. *PLoS One* 9:e91445.
- Harms CA, Maggi RG, Breitschwerdt EB, Clemons-Chevis CL, Solangi M, Rotstein DS, Fair PA, Hansen LJ, Hohn AA, Lovewell GN, et al. 2008. *Bartonella* species detection in captive, stranded and free ranging cetaceans. *Vet Res* 39:59.
- Lewbart GA, Kishimori J, Christian LS. 2005. The North Carolina State University College of Veterinary Medicine Turtle Rescue Team: A model for a successful wild-reptile clinic. *J Vet Med Educ* 32: 377–381.
- Mascarelli PE, Keel MK, Yabsley M, Last LA, Breitschwerdt EB, Maggi RG. 2014. Hemotropic mycoplasma in little brown bats (*Myotis lucifugus*). *Parasite Vectors* 7:117.
- Maggi RG, Chitwood MC, Kennedy-Stoskopf SK, Deperno CS. 2013a. Novel hemotropic *Mycoplasma* species in white-tailed deer (*Odocoileus virginianus*). *Comp Immunol Microbiol Infect Dis* 36:607–611.
- Maggi RG, Compton SM, Trull CL, Mascarelli PE, Mozayeni BR, Breitschwerdt EB. 2013b. Infection with hemotropic *Mycoplasma* species in patients with or without extensive arthropod or animal contact. *J Clin Microbiol* 51:3237–3241.
- Maggi RG, Raverty SA, Lester SJ, Huff DG, Haulena M, Ford SL, Nielsen O, Robinson JH, and Breitschwerdt EB. 2008. *Bartonella henselae* in captive and hunter-harvested beluga (*Delphinapterus leucas*). *J Wildl Dis* 44:871–877.
- Messick JB. 2004. Hemotropic mycoplasmas (hemoplasmas): A review and new insights into pathogenic potential. *Vet Clin Pathol* 33:2–13
- Middleton DM, La Flamme AC, Gartrell BD, Nelson NJ. 2014. Reptile reservoirs and seasonal variation in the environmental presence of salmonella in an island ecosystem, Stephens Island, New Zealand. *J Wildl Dis* 50:655–659.
- Ossiboff RJ, Raphael BL, Ammazalorso AD, Seimon TA, Niederriter H, Zarate B, Newton AL, McAloose D. 2015. A *Mycoplasma* species of Emydidae turtles in the northeastern USA. *J Wildl Dis* 51:466–470.
- Steer JA, Tasker S, Barker EN, Jensen J, Mitchell J, Stocki T, Chalker VJ, Hamon M. 2011. A novel hemotropic *Mycoplasma* (Hemoplasma) in a patient with hemolytic anemia and pyrexia. *Clin Infect Dis* 53:e147–e151.
- Sykes JE, Lindsay LL, Maggi RG, Breitschwerdt EB. 2010. Human coinfection with *Bartonella henselae* and two hemotropic mycoplasma variants resembling *Mycoplasma ovis*. *J Clin Microbiol* 48:3782–3785.
- Valentine KH, Harms CA, Cadenas MB, Birkenheuer AJ, Marr HS, Braun-McNeill J, Maggi RG, Breitschwerdt EB. 2007. *Bartonella* DNA in loggerhead sea turtles. *Emerg Infect Dis* 13:949–950.
- van Kuppeveld FJ, van der Logt JT, Angulo AF, van Zoest MJ, Quint WG, Niesters HG, Galama JM, Melchers WJ. 1992. Genus- and species-specific identification of mycoplasmas by 16S rRNA amplification. *Appl Environ Microbiol* 58:2606–2615.
- White G, Ottendorfer C, Graham S, Unnasch TR. 2011. Competency of reptiles and amphibians for eastern equine encephalitis virus. *Am J Trop Med Hyg* 85: 421–425.
- Work TM. 2000. *Sea turtle necropsy manual for biologists in remote refuges*. US Geological Survey National Wildlife Health Center, www.nwhc.usgs.gov/hfs/Globals/Products/turtleml.pdf. Accessed November 2017.

Submitted for publication 1 July 2017.

Accepted 15 November 2017.